

[18F]FDG-PET in a case of right temporal lobe variant of frontotemporal dementia

Marcelo Houat de Brito¹, Thiago Bezerra Moraes Teixeira¹, Poliana Fonseca Zampieri², Artur Martins Coutinho², Sonia Maria Dozzi Brucki¹

[18F] FDG-PET EM UM CASO DE VARIANTE DO LOBO TEMPORAL DIREITO DE DEMÊNCIA FRONTOTEMPORAL

Key words: positron-emission tomography, fluorodeoxyglucose F18, frontotemporal dementia.

Palavras-chave: tomografia por emissão de pósitrons, fluordeoxiglicose F18, demência frontotemporal.

A 61-year-old woman presented with a 4-year history of slowly progressive amnesic and topographical disorientation symptoms, followed by an early onset of apathy, hyperorality, ritualistic behaviors, prosopagnosia, and phonagnosia. Due to diagnostic uncertainty between Frontotemporal Dementia (FTD) and Alzheimer's Disease (AD) pathology, CSF biomarker analysis and brain [18F]FDG-PET were ordered. The first proved negative for AD profile, and

the latter demonstrated marked hypometabolism in the right temporal and frontal lobes, areas that also had asymmetric atrophy on brain MRI. These findings, together with the clinical picture, were compatible with the hypothesis of a right temporal lobe variant of FTD.^{1,2}

Author contributions. All authors contributed significantly and approved, the content of this manuscript.

REFERENCES

1. Foster NL, Heidebrink JL, Clark CM, et al. FDG-PET improves accuracy in distinguishing frontotemporal dementia and Alzheimer's disease. *Brain* 2007;130(Pt 10):2616-35.
2. Seeley WW, Bauer AM, Miller BL, et al. The natural history of temporal variant frontotemporal dementia. *Neurology* 2005;64:1384-90.

This study was conducted at Hospital das Clínicas, University of Sao Paulo School of Medicine, São Paulo, SP, Brazil.

¹Hospital das Clínicas, University of São Paulo School of Medicine, Department of Neurology, São Paulo, SP, Brazil. ²Hospital das Clínicas, University of Sao Paulo School of Medicine, Nuclear Medicine Center, Department of Radiology, São Paulo, SP, Brazil.

Marcelo Houat de Brito. Divisão de Clínica Neurológica do Hospital das Clínicas da FMUSP / Secretaria da Neurologia, Instituto Central – Av. Dr. Enéas de Carvalho Aguiar, 255 / 5º andar, sala 5084 – Cerqueira César – 05403-900 São Paulo SP – Brazil. E-mail: marcelohbrito@gmail.com

Disclosure: The authors report no conflicts of interest.

Received March 27, 2019. Accepted in final form June 13, 2019.



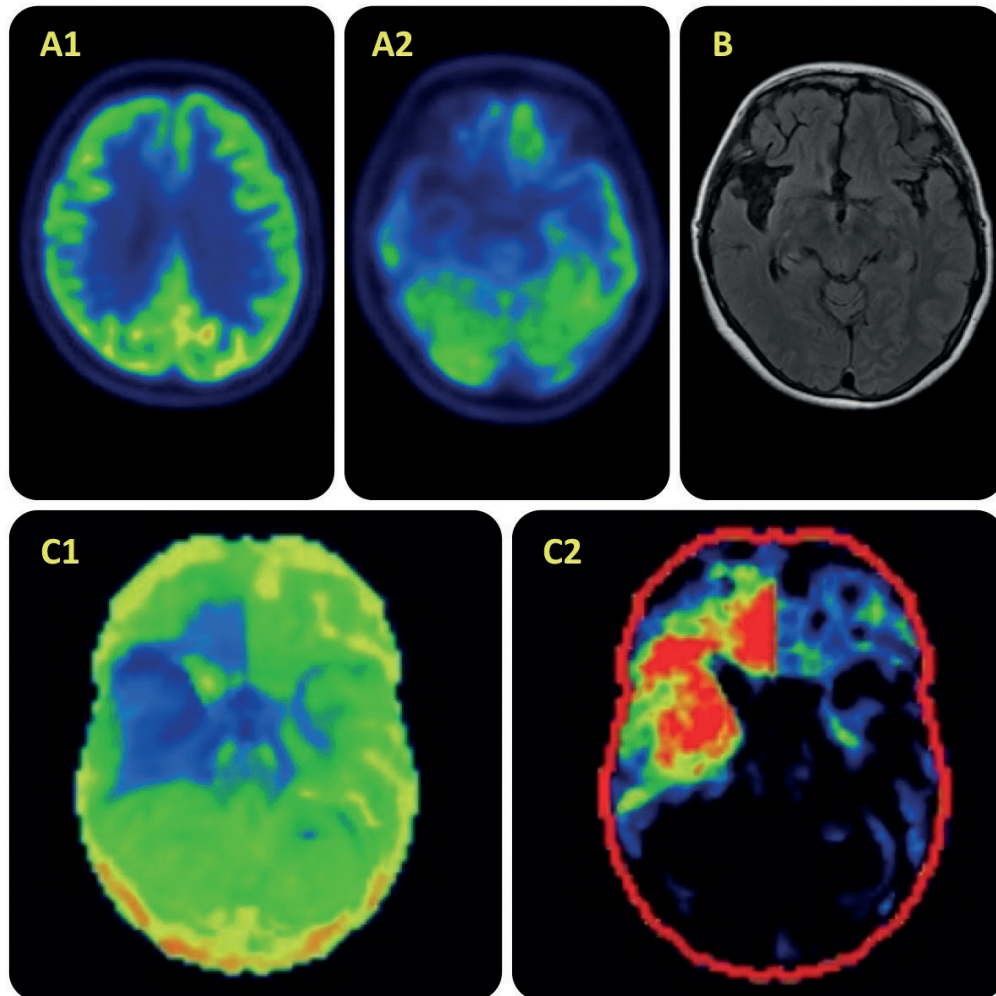


Figure. Upper row – A1, A2: [^{18}F]FDG-PET transaxial images showing prominent hypometabolism in the right temporal lobe and, to a lesser degree, in the right frontal and parietal lobes, particularly orbitofrontal areas. B – transaxial T2 FLAIR MRI image showing selective right temporal atrophy. Lower row – C1: a 3D-SSP reconstruction (inferior view) showing prominent hypometabolism in the right temporal lobe and right orbitofrontal cortex. C2 – 3D-SSP projection of comparison with a group of healthy age-matched individuals. Red areas indicate areas of lower metabolism than expected 423x423mm (72 x 72 DPI).